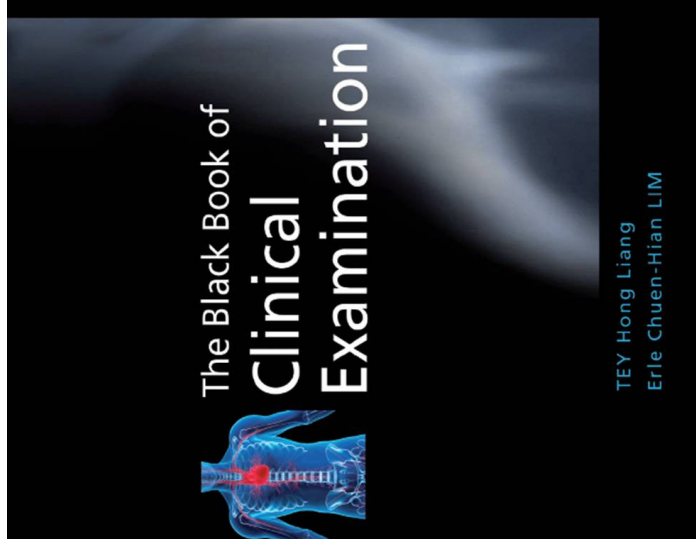

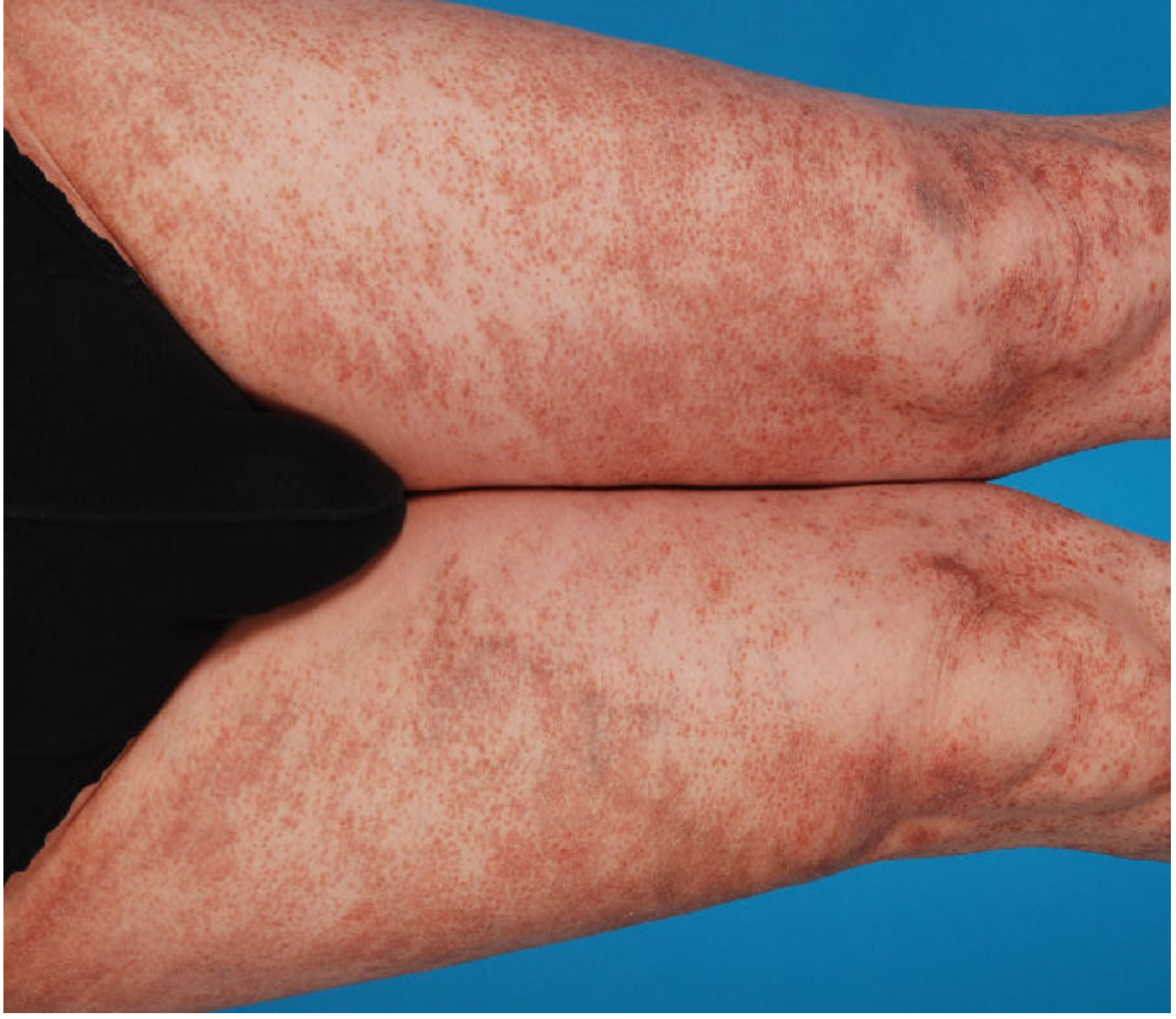Case of the Month



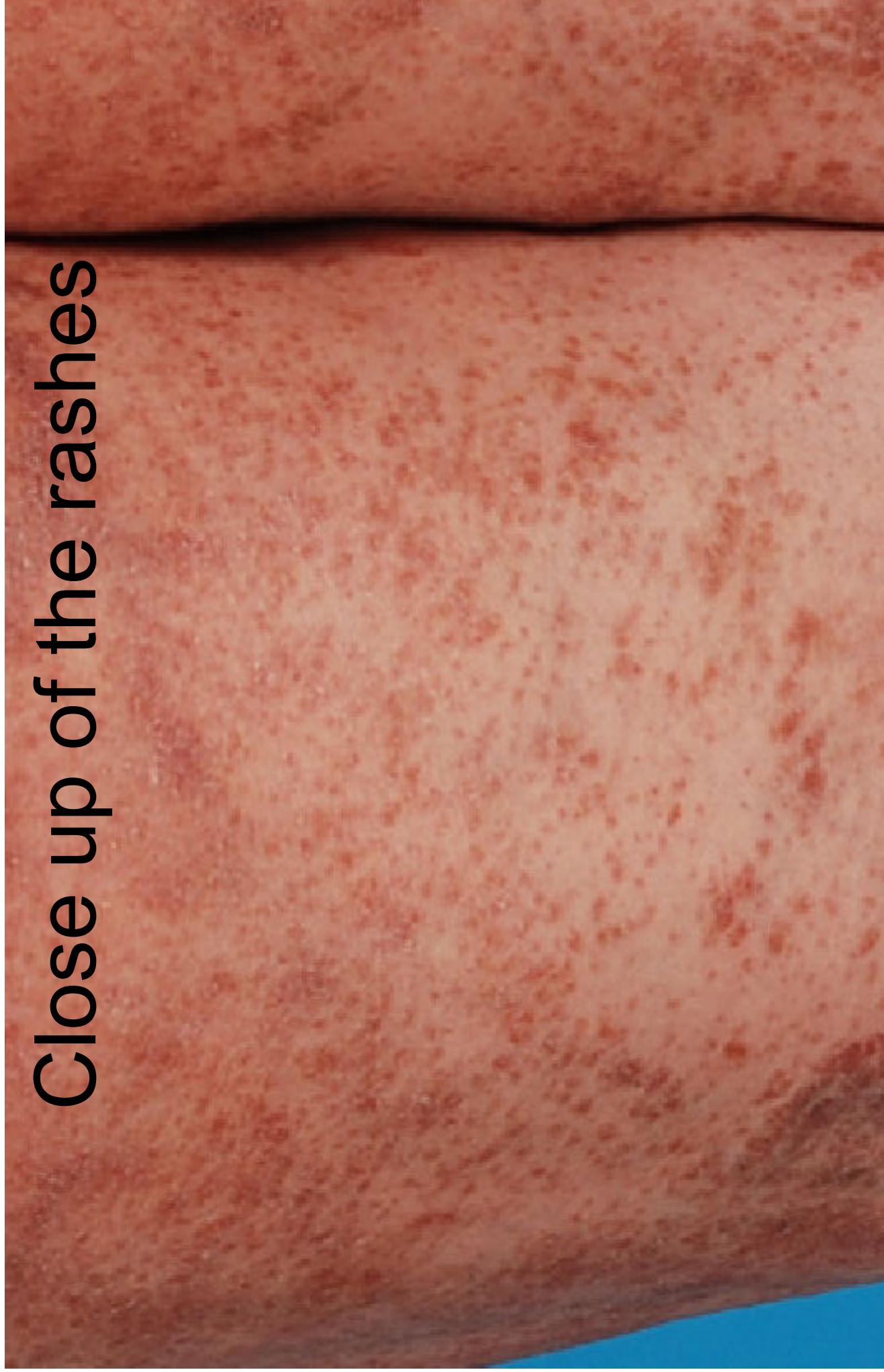Dr Tey Hong Liang
Associate Consultant
National Skin Centre

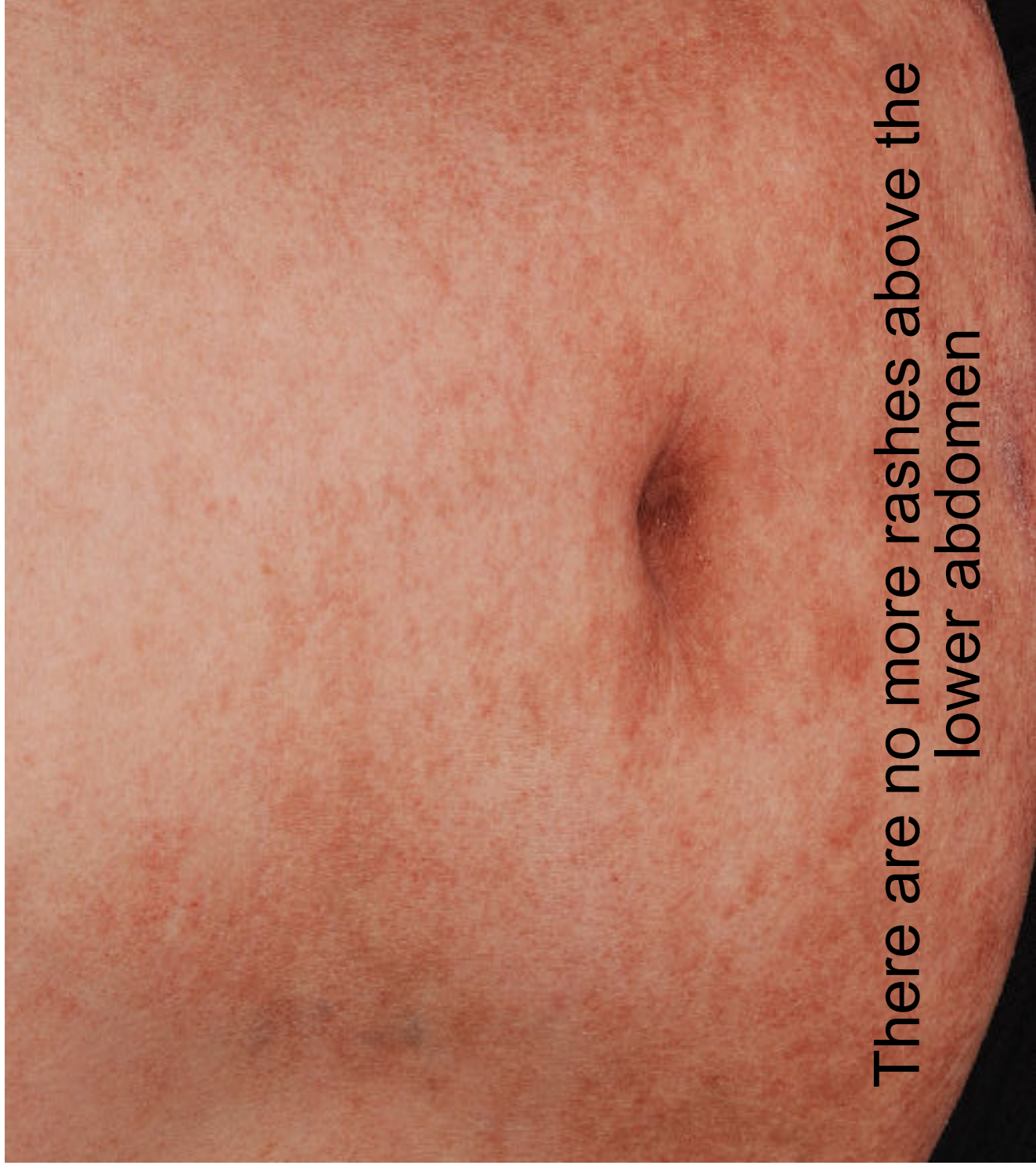
History

- A 57 year-old Chinese man complains of asymptomatic rashes over his lower limbs for 8 months. The rashes developed gradually from the lower legs and extended upwards to his waist. He applied different types of cream from different doctors but there is no improvement.
- He has a past history of deep vein thrombosis 10 years ago for which he took warfarin for a few years. He is currently not on any medication.
- He works in sales behind the desk most of the day.



Close up of the rashes





There are no more rashes above the
lower abdomen

Questions

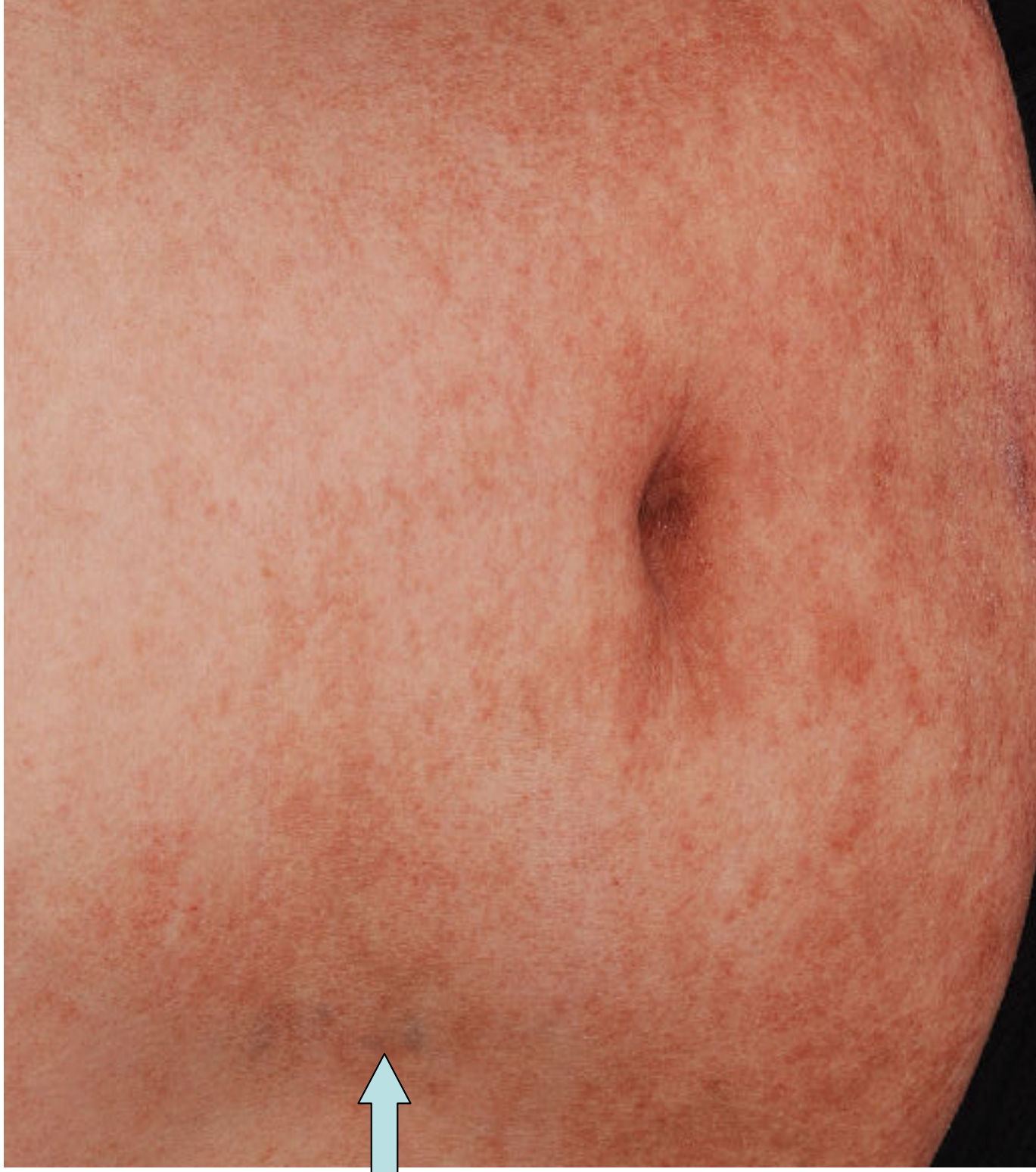
- What is the morphology of the rash? Clue: they do not blanch upon pressing.
- What other examination would you like to do?
- What diagnostic investigation would you do?

Answers

- 1. The primary morphology (see pgs 194-197 of the book) is purpura, i.e., extravasation of blood into the dermis (pg 205). In this case, the purpura looks orangy in colour, indicating that the blood leak is in the superficial dermis and therefore involves capillaries most likely. Overall, these rashes have features of pigmented purpuric dermatoses.

Answers

- 2. Refer to the photo next. Note that there is a rather sudden cut-off of the rashes at the waist. There is also a dilated vein (arrowed). You should test the direction of blood flow of the vein (see pg 29 of the book). The blood is found to flow cephalad towards the portal system.



Answers

- 3. CT scan of the abdomen and pelvis to check for thrombosis of the Inferior Vena Cava (IVC). It revealed severe thrombosis of the IVC and both branches of the iliac vein.
- The venous hypertension caudal to the level of thrombosis forced blood out of the capillaries and one should note that the rather sharp cut-off at the waist is atypical of a benign process.